

Detection of HSV-1 Encephalitis by Metagenomic Next-Generation Sequencing After Negative Conventional Testing in a Toddler with Atypical Presentation

Su Jin Joo, MD¹, Anh Vo MD¹, Elaine Cham, MD², Sudeb Dalai, MD, PhD^{3,4}, Nick Gimbrone, PhD³, Steve Miller, MD, PhD³

¹Division of Infectious Diseases and Global Health, Department of Pediatrics, UCSF Benioff Children's Hospital Oakland
²Department of Pathology, UCSF Benioff Children's Hospital Oakland ³Delve Bio, Boston, MA ⁴Stanford University School of Medicine



Background

- HSV encephalitis in children may present atypically and evade early recognition.
- Initial CSF testing may be negative or incomplete, delaying antiviral therapy.
- Diagnostic uncertainty can redirect care toward autoimmune, metabolic, or genetic etiologies.
- mNGS enables unbiased pathogen detection and can assist in unresolved cases

Clinical Presentation

21-month-old, previously healthy

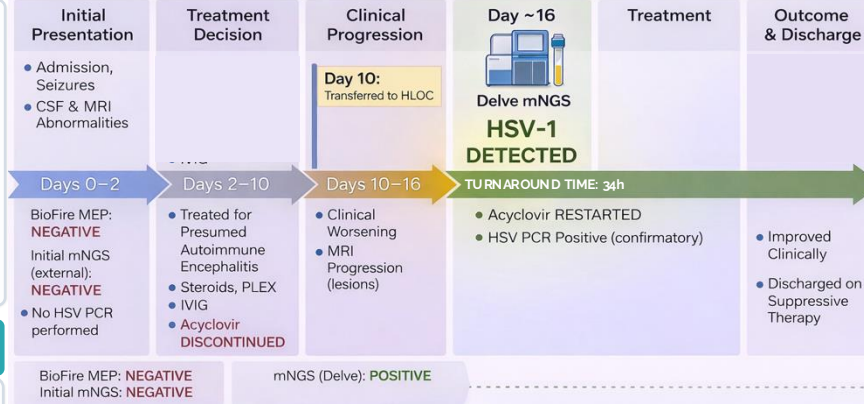
- Acute bilateral facial twitching, tongue fasciculations, confusion, afebrile
- Initial CSF (6/24/25): WBC 17 (94% lymphs), Prot 33, Glu 51
- MRI: bilateral periorlandic diffusion restriction with thalamic / basal ganglia involvement
- Broad differential: autoimmune encephalitis, infection, genetic/ metabolic etiologies

Diagnostic Uncertainty

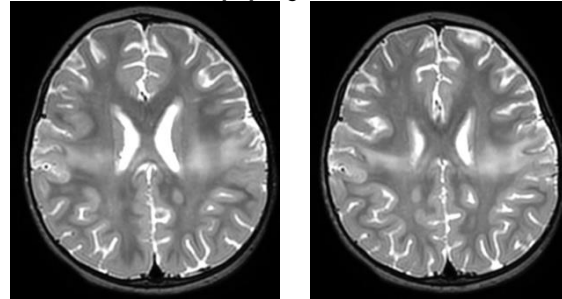
- Atypical MRI pattern (non-temporal)
- Mild CSF abnormalities
- Negative initial testing (multiplex PCR, external mNGS)
- Trajectory favoring autoimmune encephalitis -> immunotherapy
- Worsening despite immunotherapy and antiviral discontinuation

CSF sent for mNGS to evaluate unresolved encephalitis

Clinical Case Timeline

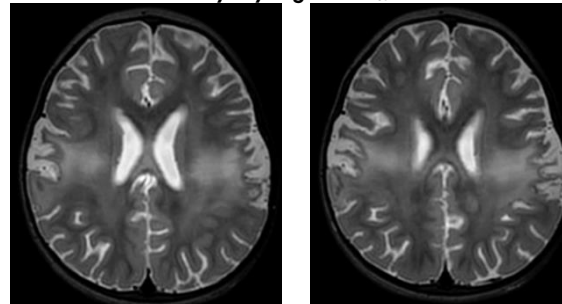


7/7/25 MRI Brain



(No contrast) Compared to 6/30/25, interval progression. Increased T2 signal and diffusion restriction, bilateral periorlandic (frontal/parietal) and central thalamic nuclei.

7/17/25 MRI Brain

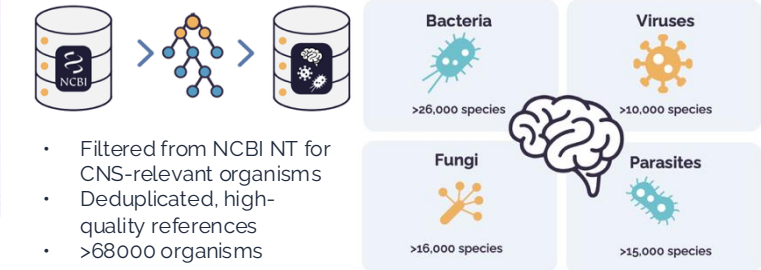


(Contrast) Evolving injury. Progressive periorlandic cortical thinning & encephalomalacia. New punctate cavitations/necrosis in the thalamus. Increased T2/FLAIR signal in corona radiata. No new areas of involvement. Consistent with evolving meningoencephalitis, mitochondrial/metabolic etiology.

Pathogen Detection Through mNGS



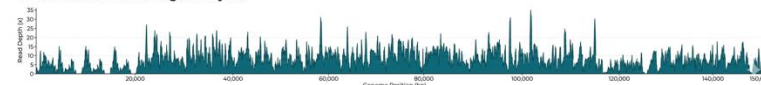
Curated Pathogen Database



Sequencing Results and Interpretation

HUMAN HERPESVIRUS 1 (HSV-1) mNGS Genome Coverage Analysis

Total Reads	Mean Depth	Coverage	Contig Length	K Covered Bases	Mean Base Q	Mean Map Q
7,526	5.28x	88.25%	150,670 bp	132,971 bp	255.0	52.50



- HSV-1 detected in CSF by mNGS
- 4,889 reads / ~19 million total reads, broad (~88%) genomic coverage
- Sequence alignment with >99% identity
- **UL23 thymidine kinase (34 reads):** No resistance-associated mutations or indels detected; consistent with wild-type HSV-1.

Conclusions

- mNGS identified HSV-1 after negative initial testing and clinical deterioration
- Prompted re-initiation of acyclovir with improvement
- Demonstrates utility of mNGS in evolving encephalitis, including when clinical course and testing are incongruent