Pediatric Blood & Cancer

WILEY

Pediatric Blood & Cancer | SIOP International Society of Paediatric Oncology | aspho The American Society of Pediatric Hematology/Oncology

LETTER TO THE EDITOR

Fatal Neuroinvasive Astrovirus VA1 Encephalitis in a Child With High-Risk B-ALL Receiving Blinatumomab

Alaric W. D'Souza[1,2,3] | Pietro Miozzo[4] | Molly Wilson-Murphy[5] | Andrew E. Place[4] | Sudeb Dalai[6,7] | Steve Miller[7,8] | Ofer Levy[1,3,9,10] | Seth Rakoff-Nahoum[1,3,9]

[1]Division of Infectious Diseases, Boston Children's Hospital, Boston, Massachusetts, USA | [2]Department of Immunology and Infectious Diseases, Harvard T.H. Chan School of Public Health, Boston, Massachusetts, USA | [3]Harvard Medical School, Boston, Massachusetts, USA | [4]Dana-Farber/Boston Children's Cancer and Blood Disorders Center, Harvard Medical School, Boston, Massachusetts, USA | [5]Division of Neurology, Boston Children's Hospital, Boston, Massachusetts, USA | [6]Division of Infectious Diseases and Geographic Medicine, Department of Medicine, Stanford University School of Medicine, Stanford, California, USA | [7]Delve Bio, Boston, Massachusetts, USA | [8]Department of Laboratory Medicine, University of California San Francisco, San Francisco, California, USA | [9]Precision Vaccines Program, Boston Children's Hospital, Boston, Massachusetts, USA | [10]Broad Institute of MIT & Harvard, Cambridge, Massachusetts, USA

Correspondence: Seth Rakoff-Nahoum (Seth.Rakoff-Nahoum@childrens.harvard.edu)

Received: 29 July 2026 | **Revised:** 29 July 2026 | **Accepted:** 4 August 2026

To the Editor:

Human astroviruses classically cause self-limited gastroenteritis, but Virginia/human-mink-ovine-like (VA/HMO) strains can cause severe encephalitis in immunocompromised hosts [1–4]. Diagnosis is challenging because routine cerebrospinal fluid (CSF) and gastrointestinal assays do not detect these neuroinvasive strains [5–7]. We report fatal astrovirus VA1 encephalitis in a child with high-risk B-cell acute lymphoblastic leukemia (B-ALL) treated with chemotherapy and blinatumomab. This case adds to the limited pediatric oncology experience with neuroinvasive astrovirus and highlights blinatumomab-induced humoral deficiency as a previously unrecognized potential risk factor.

A previously neurotypical 4-year-old male with *IKZF1*-deleted B-ALL receiving treatment as per the very high-risk arm of DFCI 16-001 presented during consolidation therapy, 10 months after remission and 3 months after completing his second blinatumomab cycle. Three days before admission, he developed progressive somnolence, unsteady gait, and anorexia. He was afebrile and hemodynamically stable but nonverbal, responsive only to noxious stimuli, and unable to follow commands, with truncal ataxia and a wide-based gait. Laboratory testing demonstrated neutropenia (1070 cells/μL), lymphopenia (1020 cells/μL), and profound hypogammaglobulinemia (IgG 41 mg/dL). Metabolic studies and C-reactive protein were normal. Brain magnetic resonance imaging (MRI) and magnetic resonance angiography were normal on hospital day (HD)1. CSF showed minimal inflammation (4 white blood cells/μL, protein 21.5 mg/dL, glucose 47 mg/dL), and electroencephalography demonstrated generalized slowing without seizures. Intravenous immunoglobulin was administered.

By HD4, MRI demonstrated diffuse leptomeningeal and perivascular enhancement. He developed acute right-sided weakness and worsening somnolence on HD6. Repeat MRI on HD7 showed new bilateral hippocampal T2 abnormalities without infarction (Figures 1 and 2). Repeat CSF remained minimally inflammatory. Standard infectious testing was unrevealing, but CSF metagenomic next-generation sequencing (mNGS) detected astrovirus VA1. Retrospective mNGS of the initial HD1 CSF also detected astrovirus VA1 with higher signal, supporting infection early in the clinical course. An autoimmune encephalitis evaluation was negative. Serial CSF cytology and bone marrow evaluation showed no evidence of leukemia relapse.

Astrovirus-directed treatment included nitazoxanide from HD11-73, ribavirin from HD11-41, peginterferon-α-2a weekly for four doses, and immunoglobulin replacement, based on published case experience and preclinical data [5, 8–10].

Ribavirin and peginterferon were discontinued after pancreatitis developed. Serial stool multiplex PCR testing remained negative for astrovirus. Neuroimaging showed partial improvement in limbic and meningeal abnormalities, but progressive involvement

All rights reserved, including rights for text and data mining and training of artificial intelligence technologies or similar technologies.
© 2026 Wiley Periodicals LLC.

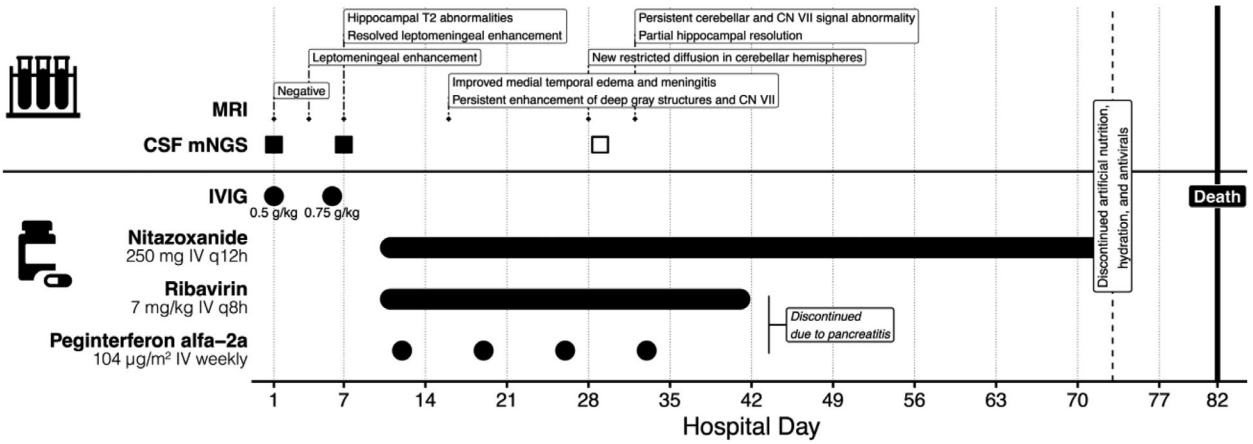

FIGURE 1 | Diagnostic and treatment timeline. Hospitalization timeline showing serial MRI findings, CSF mNGS results, and immunomodulatory and antiviral therapies. In the upper panel, MRI timing is indicated by small diamonds, and attached labels give key MRI findings. Filled squares indicate astrovirus-positive CSF mNGS results, and open squares indicate negative results. The lower panel shows medication timing and doses where points indicate discrete administrations, and horizontal bars indicate treatment courses. Death occurred on hospital day 82.

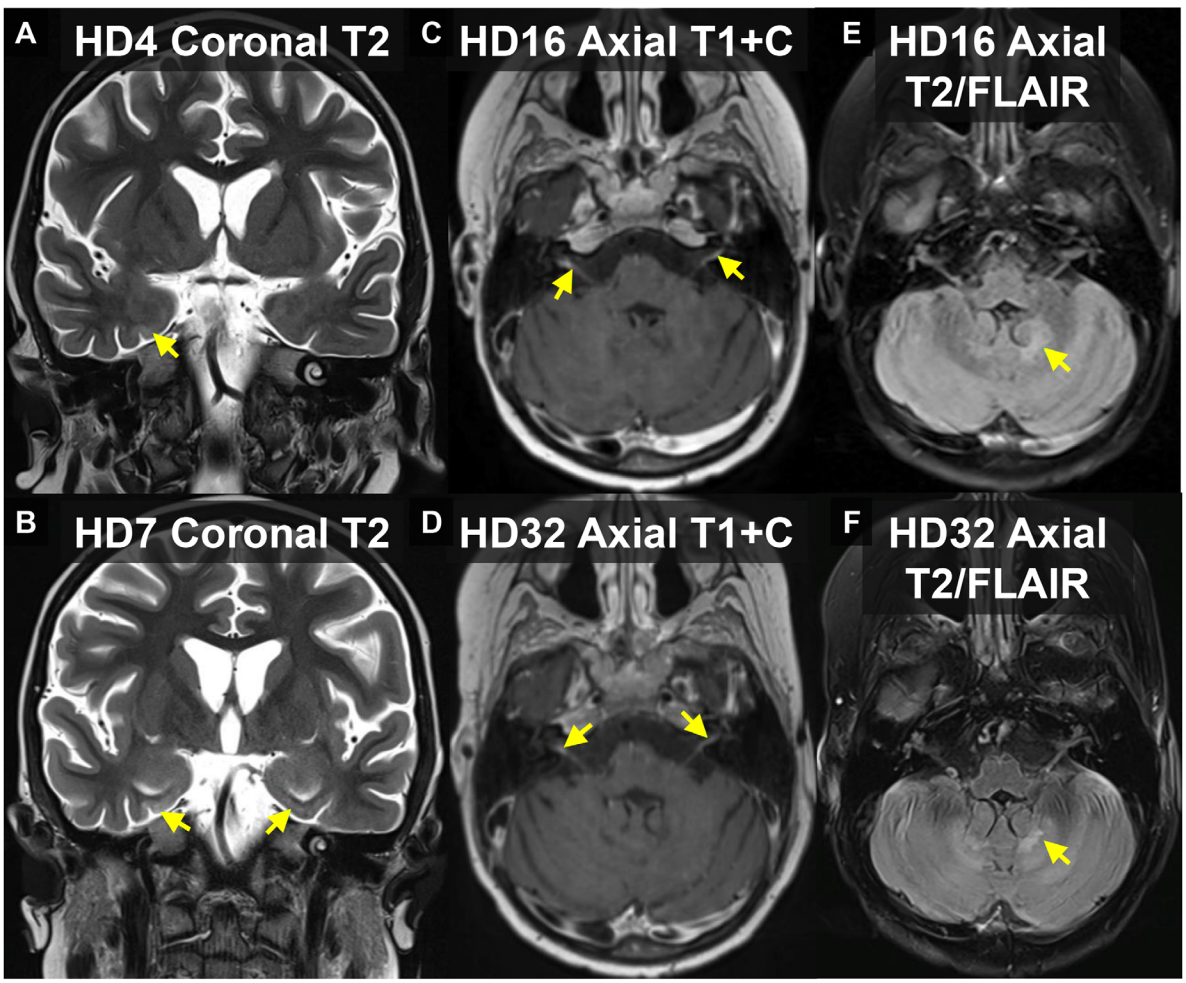

FIGURE 2 | MRI brain findings during hospitalization. (A) Hospital day (HD)4: Coronal T2 demonstrating signal abnormality involving the posterior aspect of the right hippocampus at its transition with the fimbria. (B) HD7: Coronal T2 showing interval evolution with persistent abnormal T2 hyperintensity and decreased diffusivity of the right hippocampal formation, with equivocal trace decreased diffusivity of the left hippocampal formation. (C) HD16: Axial T1 demonstrating subtle perivascular enhancement within the bilateral deep gray nuclei and enhancement along cranial nerves III, V, VII, and VIII bilaterally, with decreased but persistent enhancement of the cerebellar folia. (D) HD32: Axial T1 showing less pronounced linear enhancement within the internal auditory canals along cranial nerves VII and VIII. (E) HD16: Axial T2 demonstrating signal abnormality involving the cerebellar dentate nuclei. (F) HD32: Axial T2 showing progression with slightly more pronounced signal abnormality and decreased diffusivity involving the cerebellar dentate nuclei.

of the deep gray structures, cranial nerves, and cerebellum. While astrovirus was no longer detected by CSF mNGS on HD29, the patient remained minimally arousable and nonverbal and developed a progressive hyperkinetic movement disorder without electrographic seizures. Chemotherapy was held throughout admission. Because meaningful neurologic recovery did not occur, care was redirected on HD73, and he died on HD82.

Humoral immunodeficiency is a recognized risk factor for severe astrovirus disease [3–6]. Blinatumomab is a bispecific T-cell engager that induces T-cell-mediated depletion of CD19-positive leukemic and normal B cells and can produce prolonged B-cell aplasia and hypogammaglobulinemia [11]. This effect is akin to other inborn errors of humoral immunity that increase risk for astrovirus such as X-linked agammaglobulinemia [12, 13]. In children with B-ALL, blinatumomab may compound disease- and chemotherapy-associated immune dysfunction.

This case also highlights two diagnostic challenges. First, neuroinvasive astrovirus may present with initially normal MRI and minimally inflammatory CSF, while routine CSF, blood, and stool diagnostic testing does not target neurotropic VA/HMO astrovirus strains [4–6]. Early CSF mNGS should be considered in immunocompromised children with unexplained progressive encephalopathy. Earlier recognition may also avoid prolonged empiric treatment for alternative diagnoses or the need for invasive brain biopsy. Second, there is no established treatment for neuroinvasive astrovirus. Although combination therapy coincided with CSF viral clearance, neurologic injury progressed, and clearance cannot be attributed to any single agent. Discordance between virologic and clinical outcomes suggests that diagnosis and treatment may need to precede substantial tissue injury.

This patient's profound hypogammaglobulinemia and onset of neuroinvasive astrovirus infection after two blinatumomab courses underscores unresolved, but urgent clinical questions as B-cell-directed therapy becomes increasingly integrated into frontline pediatric B-ALL treatment [11].

Prospective studies are needed to understand the progression of immune reconstitution after blinatumomab, to define the potential severe viral infection risk, and to develop a risk-minimizing protocol for IgG surveillance and replacement.

Acknowledgments

We thank the patient's family for granting permission to share this case. We also acknowledge the Boston Children's Hospital Neuroradiology team for their interpretation of the MRI studies. A.W.D. was supported by an NIH institutional training grant (NIH/NIAID 5T32AI155391-05) and by the St. Jude Children's Research Hospital-Pediatric Infectious Diseases Society Fellowship Program in Basic and Translational Research. No direct NIH funding was allocated for this work.

Disclosure

This study was not designed as a clinical trial and therefore does not have a clinical trial registration number.

Ethics Statement

Written informed consent for publication was obtained from the patient's parent. All patient information has been de-identified to protect confidentiality. This case report was conducted in accordance with the institutional ethical guidelines and did not require additional institutional review board approval.

Conflicts of Interest

O.L. is a named inventor on patents held by Boston Children's Hospital related to vaccine adjuvants and antigens as well as human in vitro systems that model the safety and immunogenicity of vaccines and immunotherapeutics. O.L.'s laboratory receives sponsored research support from, and he is a consultant to, *GlaxoSmithKline* (GSK). He is a co-founder of *ARMR Sciences*.

Data Availability Statement

Relevant sequencing files will be available by 2027-02-01 or on publication (whichever is sooner) in the NCBI Sequence Read Archive (SubmissionID: SUB15939320, BioProject ID: PRJNA1404327).

References

1. M. P. Olortegui, S. Rouhani, P. P. Yori, et al., "Astrovirus Infection and Diarrhea in 8 Countries," *Pediatrics* 141 (2018): e20171326, https://doi.org/10.1542/peds.2017-1326.

2. V. Cortez, P. Freiden, Z. Gu, E. Adderson, R. Hayden, and S. Schultz-Cherry, "Persistent Infections With Diverse Co-Circulating Astroviruses in Pediatric Oncology Patients, Memphis, Tennessee, USA," *Emerging Infectious Diseases* 23 (2017): 288–290, https://doi.org/10.3201/eid2302.161436.

3. G. Reuter, P. Pankovics, and Á. Boros, "Nonsuppurative (Aseptic) Meningoencephalomyelitis Associated With Neurovirulent Astrovirus Infections in Humans and Animals," *Clinical Microbiology Reviews* 31 (2018): e00040–18, https://doi.org/10.1128/CMR.00040-18.

4. J. R. Brown, S. Morfopoulou, J. Hubb, et al., "Astrovirus VA1/HMO-C: An Increasingly Recognized Neurotropic Pathogen in Immunocompromised Patients," *Clinical Infectious Diseases* 60 (2015): 881–888, https://doi.org/10.1093/cid/ciu940.

5. M.-L. Frémond, P. Pérot, E. Muth, et al., "Next-Generation Sequencing for Diagnosis and Tailored Therapy: A Case Report of Astrovirus-Associated Progressive Encephalitis," *Journal of the Pediatric Infectious Diseases Society* 4 (2015): e53–e57.

6. S. H. Lum, A. Turner, M. Guiver, et al., "An Emerging Opportunistic Infection: Fatal Astrovirus (VA1/HMO-C) Encephalitis in a Pediatric Stem Cell Transplant Recipient," *Transplant Infectious Disease: An Official Journal of the Transplantation Society* 18 (2016): 960–964, https://doi.org/10.1111/tid.12607.

7. S. N. Naccache, K. S. Peggs, F. M. Mattes, et al., "Diagnosis of Neuroinvasive Astrovirus Infection in an Immunocompromised Adult With Encephalitis by Unbiased Next-Generation Sequencing," *Clinical Infectious Diseases* 60 (2015): 919–923, https://doi.org/10.1093/cid/ciu912.

8. V. Hargest, B. Sharp, B. Livingston, V. Cortez, and S. Schultz-Cherry, "Astrovirus Replication Is Inhibited by Nitazoxanide in Vitro and in Vivo," *Journal of Virology* 94 (2020): e01706–e01719, https://doi.org/10.1128/JVI.01706-19.

9. A. B. Janowski, H. Dudley, and D. Wang, "Antiviral Activity of Ribavirin and Favipiravir Against Human Astroviruses," *Journal of Clinical Virology* 123 (2020): 104247, https://doi.org/10.1016/j.jcv.2019.104247.

10. S. A. Marvin, C. T. Huerta, B. Sharp, P. Freiden, T. D. Cline, and S. Schultz-Cherry, "Type I Interferon Response Limits Astrovirus Replication and Protects Against Increased Barrier Permeability in Vitro and in Vivo," *Journal of Virology* 90 (2016): 1988–1996, https://doi.org/10.1128/JVI.02367-15.

11. S. Gupta, R. E. Rau, J. A. Kairalla, et al., "Blinatumomab in Standard-Risk B-Cell Acute Lymphoblastic Leukemia in Children," *New England Journal of Medicine* 392 (2025): 875–891, https://doi.org/10.1056/NEJMoa2411680.

12. G. Zugmaier, M. S. Topp, S. Alekar, et al., "Long-Term Follow-Up of Serum Immunoglobulin Levels in blinatumomab-treated Patients With Minimal Residual Disease-positive B-precursor Acute Lymphoblastic Leukemia," *Blood Cancer Journal* 4 (2014): 244, https://doi.org/10.1038/bcj.2014.64.

13. A. H. Long, C. Aftandilian, S. Barmettler, and S. Alexander, "Hypogammaglobulinemia in Children Receiving Targeted Immunotherapies for B Lineage Malignancies: Practical Guidance for Assessment and Management," *Pediatric Blood & Cancer* 72 (2025): e31779, https://doi.org/10.1002/pbc.31779.